

Long-term urological outcome of men born with hypospadias

Anne-Françoise Spinoit
@AFSpinoit

Department of Urology, University Hospital Ghent, Belgium



INTRODUCTION

External genital reconstruction is challenging
Voiding function in childhood → sexual function in adulthood

Pubertal growth

Sexual and reproductive functions → effect on adult life

Complications can arise many years after surgery

Focus on cosmesis, psychosocial and functional outcome



INTRODUCTION

More than 300 techniques described for reconstruction
No good prospective or controlled trials
No good tools to judge cosmesis
No guidelines on how to measure psychosexual and psychosocial outcomes



INTRODUCTION

Which outcomes are important on long term?
Voiding function (strictures, fistulae, diverticulae)
Cosmesis (scars, skin distribution)
Sexual function (erection, ejaculation, curvature, sensitivity)



INTRODUCTION

Spraying (NR -63 %)
Post void dribbling (NR -30 %)
Stream deviation (NR -26%)
LUTS (NR -20 %)
Severe LUTS (NR- 4 %)
Fistulae (0% - 25 %)
Strictures (0% - 8 %)
Uroflow Qmax < 95th percentile (NR- 3,7% -14,7%)



PARTICIPANTS

Hypospadias	N= 192
Distal	132/192 (68,8%)
Midshaft	37/192 (19,3%)
Proximal	23/192 (12,0%)
Complex	20/192 (10,4%)
Controls	N=50



UROLOGICAL OUTCOME ?

Uroflow
 Post-void ultrasound
 Genital exam
 Scrotal ultrasound (varicocele)



UROLOGICAL OUTCOME ? : UROFLOW

Abnormal: 36/192 (18,8%)
 Mostly plateau curve
 Grade of hypospadias made no difference
 (p=0,581)
 Only 5 men with post-void with residue
 No proximal cases



UROLOGICAL OUTCOME ? : GENITAL EXAM

Fistulae: 11/192 (5,7%)
 no difference severity hypospadias (p=0,229)
Residual hypospadias: 47/192 (24,5%)
 More in proximal HS (52,2%, p=0,003)
Testicular microcalcifications:
 Hypospadias: 13/191 (6,8%)
 No difference: Controls (6%);
 No difference within grade of hypospadias (NS)
High prevalence of varicocele



UROLOGICAL OUTCOME ? : GENITAL EXAM

Journal of Pediatric Urology 2016; 11, 321-324

Appraisal of adult genitalia after hypospadias repair: Do laypersons mind the difference?

Norma K. Ruppen-Greeff ^{1,2}, Markus A. Landolt ^{3,4,5}, Rita Gobet ^{1,2}, Daniel M. Weber ^{1,2}

Summary
 Men with corrected hypospadias often suffer from sexual inhibition and fear of being ridiculed by others because of their penile appearance. However, no investigation has tried to assess the perception of hypospadias-affected genitalia by laypersons. Therefore, the aim of this study was to assess whether laypersons could distinguish between genitalia of men with corrected hypospadias and genitalia of men with circumcised genitalia. Furthermore, the most-relevant predictors of laypersons' perception of hypospadias-affected genitalia were examined.

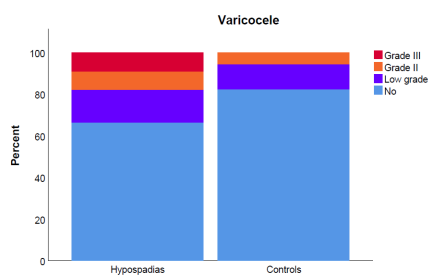
Study design
 A cross-sectional study was performed in which a questionnaire with 10 standardized photographs of circumcised hypospadias-affected genitalia and 10 circumcised genitalia was presented to laypersons, accompanied with hypospadias to measure how they rated these genitalia. Laypersons were 105 women and 105 men, 20-30- and 40-50-year-olds. Furthermore, laypersons were asked about demographic characteristics, their anxiety and their genital self-perception.

Results
 The results showed that genitalia with distal forms of hypospadias were rated similarly to circumcised genitalia. In contrast, genitalia with more proximal forms were perceived as significantly less attractive than circumcised genitalia. However, the effect size

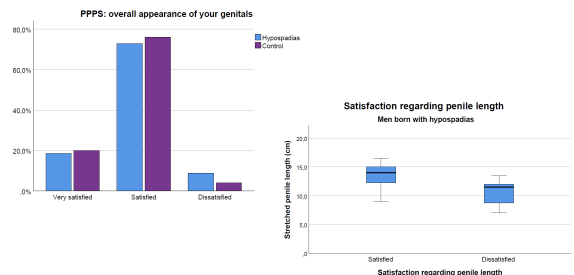
Conclusions
 The results are relevant for patient counselling. Knowing that the penile appearance would not enable laypersons to prevent the development of a negative genital self-perception and feelings of shame, that findings also suggest that hypospadias-affected genitalia seem to be rated more positively when laypersons have knowledge about the "normal" results of distal operations. In addition, with increasing sexual experience at a higher age,



UROLOGICAL OUTCOME ? : SCROTAL ULTRASOUND



UROLOGICAL OUTCOME ? : GENITAL EXAM



CONCLUSIONS

Nothing is 'minimal hypospadias', expert hands important

Outcome ?

Evaluation of esthetic patient versus surgeon

High rate of varicocele post HS surgery of unclear origin so far

Need for postpubertal follow-up of HS cases as long-term complications may occur



THANK YOU !

