




AN EXCEPTIONAL CASE OF USING 68 GALLIUM PSMA-PET / CT FOR TARGETING PROSTATE BIOPSIES

SLAOUI AMINE

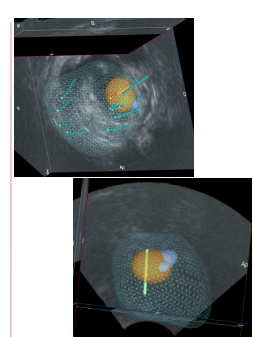
BAU 2018
18th ANNUAL CONGRESS
BELGIAN ASSOCIATION OF UROLOGY

Urology B Department Ibsina Hospital Rabat MOROCCO
IBN ATTYA Ahmed
Urology Department Erasme Hospital Brussels BELGIUM
ROUMEGUÈRE Thierry
Urology Department Bordet Institut Brussels BELGIUM
PELTIER Alexandre



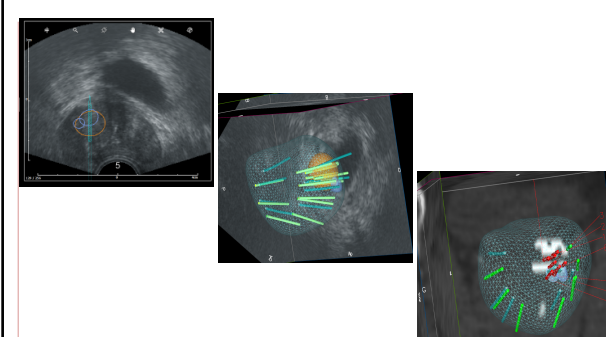
The Patient

- 69-year-old caucasian patient
- No specific history
- Urological consultation for Pca screening
- PSA 13 ng/ml
- First systematic biopsy series
→ **NEGATIVE**
- MP MRI: PIRADS 4 at the right baseline
- Second biopsy guided by Koelis MRI image fusion
→ **NEGATIVE**




The Patient

- PSA \nearrow 27 ng / ml
- Multidisciplinary meeting: 68Ga-PSMA PET / CT
- « Avid » spot of PSMA in the prostate Ant/Base right displaced from the MRI
- No sign of local metastasis or distance
- 3-D model (Koelis Software)
 - PSMA ROI (BLUE)
 - MRI ROI (YELLOW)




Biopsy N3: 8 target biopsies + 12 systematic



Results

Biopsy	Length	Tumor size	Gleason
1	18	5	4+3
2	17	6	4+3
3	20	8	4+3
4	17	6	4+3
5	16	5	3+4
6	16	5	3+4
7	17	9	4+3
8	17	4	3+4



Discussion

- Compared to conventional staging, PSMA PET / CT changed disease management:
 - Albisinni et al: 76% of patients
 - Roach et al: 62% of patients
- Monni et al: **10%** of significant lesions are still MRI-invisible
- 2 cases of targeted biopsy guided by images of PET CT PSMA:
 - Zettinig O et al. 2015
 - Simopoulos DN et al 2017
- Our experience: 5 cases → **1 remains NEGATIVE**



Discussion

Expensive + difficult to obtain in most establishments
But finds all its interest in difficult and rare cases like this one



7



Conclusion

- Patient with a very high PSA level
- 2 sets of biopsies (standard and by MRI image fusion) both returned negative.
- Cancer detected by fusion-guided biopsy of 68Ga-PSMA PET and real-time ultrasound (FRANCE PET Choline- JL Bonnal)
- New application of PET 68Ga-PSMA ?
 - Initial diagnosis of prostate cancer difficult to find
 - Better delineation for focal therapy
 - Metabolique > dynamique??



**"WE ARE ALL IN THE GUTTER...
...BUT SOME OF US ARE LOOKING AT THE STARS"**

8



Thank you for your attention

9